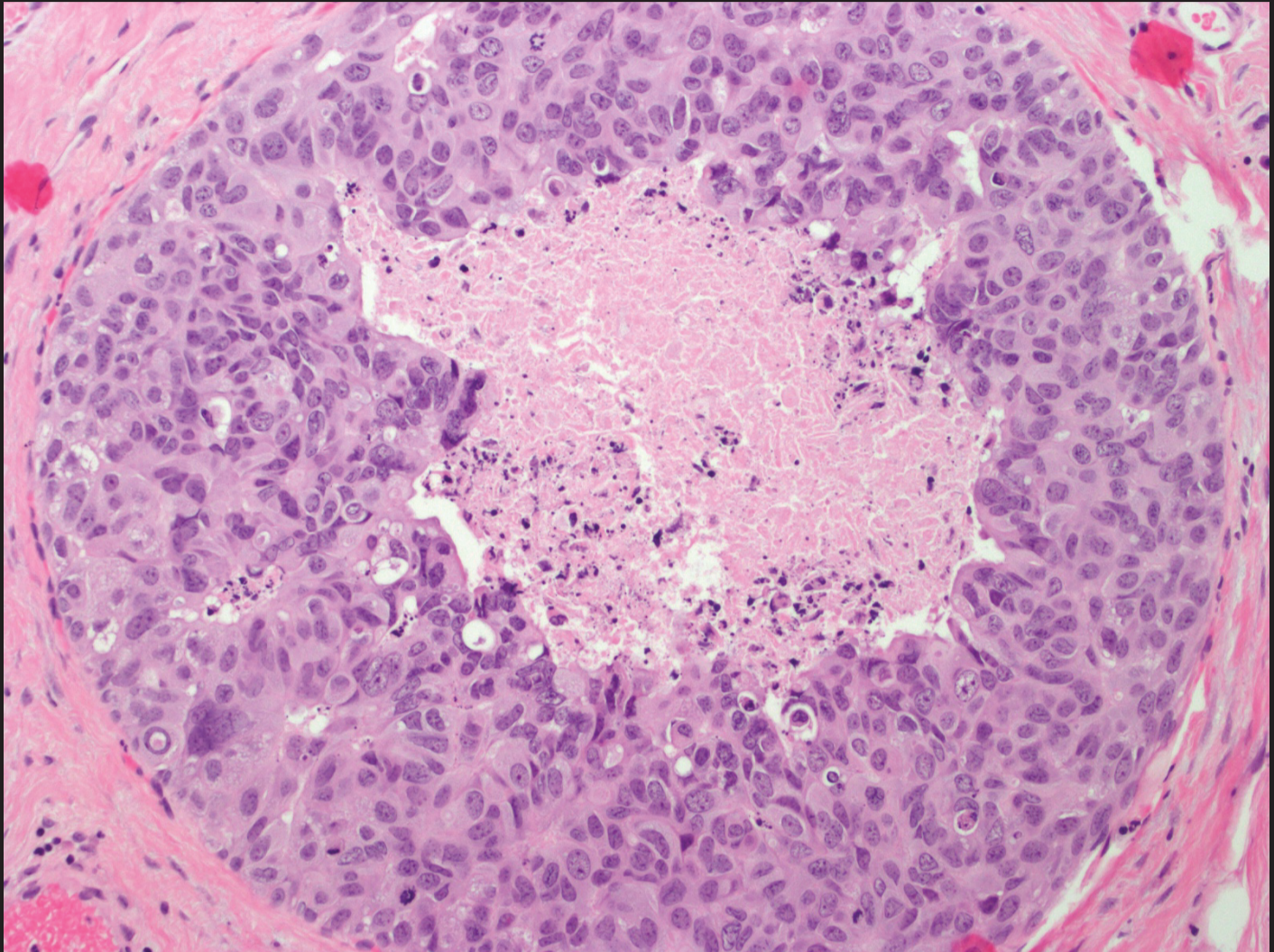


Haematoxylin and eosin stained sections of breast biopsies showing duct carcinoma in situ (DCIS, upper panel) and invasive duct carcinoma (lower panel)

Duct carcinoma in situ



Invasive duct carcinoma

x20

